GREATER COLUMBUS PERIODONTICS
RYAN J. SERRA, DMD, MS
Practice Limited to Periodontics
Dental Implants

OCTOBER 2017 NEWSLETTER

ALTERED ACTIVE AND PASSIVE ERUPTION: A MODIFIED CLASSIFICATION

Esthetic dental therapy related to a "perfect smile" has become very important in contemporary clinical dentistry. Among smile disharmonies, excessive gingival tissue, frequently called a "gummy smile," can be associated with vertical maxillary growth, dentoalveolar extrusion, short upper lip, upper lip hyperactivity, altered passive eruption (APE), or a combination of these factors.

Passive Eruption

Tooth exposure secondary to apical migration of the gingival margin to a location at or slightly coronal to the CEJ

Altered Passive Eruption (APE)

A genetic or developmental condition characterized by coronal positioning of the gingival margin over enamel, resulting in short clinical crowns

Active Eruption

The process by which a tooth moves from its germinative position to its functional position in occlusion with the opposing arch

Altered Active Eruption (AAE)

This occurs when teeth achieve the opposite relationship to the occlusal plane prematurely and the osseous crest is on or very close to the cemento-enamel junction

American Academy of Periodontology. *Glossary of Periodontal Terms*, March 2016.

In 1933, Gottlieb and Orban aimed to describe dental eruption phases and divided them into active and passive dental eruption. Eruptive processes initiate with ***active dental eruption***, characterized by tooth eruption from the osseous crypt, disruption of the oral epithelium, and establishment of occlusal contact with the antagonist tooth. ***Passive dental eruption*** is defined as apical migration of gingival tissue until accommodation on, or very close to, the cemento-enamel junction (CEJ), determining gingival margin (GM) position. After disruption of the oral epithelium, both processes continue simultaneously. These events are part of the determination of dentogingival union and the establishment of biologic width (Cairo F et al, 2012; Evian A et al, 1993). **Altered Passive Eruption (APE)** is characterized by a coronal position of gingival tissue over enamel, resulting in the appearance of short clinical crowns. **Altered active eruption (AAE)** is characterized by proximity or coincidence of the alveolar crest to the CEJ (Amsterdam ME, 1991). Although APE leads to esthetic impairment, this situation is a normal variation and not necessarily pathologic (Volchansky A et al, 1974). Generally, APE prevalence is more common in individuals with a thick gingival biotype. However, data regarding the prevalence of APE or AAE in adults is scarce. Age is a fundamental factor for a correct diagnosis, as eruptive processes achieve balance around 20 years of age (Nart J et al, 2014; Steedle JR, 1985).

The most accepted classification for APE was published by Coslet et al (1977). This is characterized by:

1. The amount of keratinized gingiva (Type I: wide gingiva; Type II: thin gingiva)
2. The distance from the CEJ to the alveolar crest (subgroup A: alveolar crest and CEJ relationship corresponds to the 1.5-mm distance accepted as normal biologic width; subgroup B: alveolar crest is at the level of the CEJ)

The type of treatment proposed for many cases of APE are based on this classification. However, important biologic principles, such as association with AAE, are not well described. Despite simultaneous occurrence, AAE and APE are different events that may or may not be associated with each other. Based upon this concept, a modification of the current classification is suggested based on eruptive and biologic concepts.

This modified classification preserves APE Type I and Type II according to the amount of keratinized gingiva, but values were inserted to facilitate a diagnosis (Type I: >2 mm of keratinized tissue; Type II: £2 mm). Another important modification is the exclusion of subgroups A and B and the inclusion of categories APE alone or APE associated with AAE (Fig. 1)

Several methods have been proposed to diagnose AAE. A traditional method, recommended by Coslet, compares periapical radiographs and periodontal probing, demonstrating the distance between the alveolar crest and the CEJ. Another technique that may be used is trans-sulcus periodontal probing. More recently, Janua proposed utilizing CBCT to allow a more precise localization of the osseous crest and gingival tissue thickness.

(Ragghianti Zangrando M et al, *Clin Adv Periodontics* 2017;7:51-56)

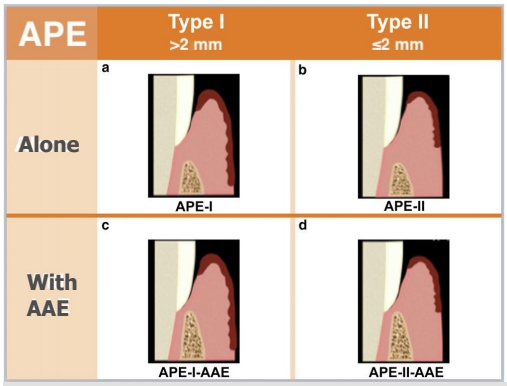

FIGURE 1-Modified classification of APE & AAE

- **1a**—APE-I: Keratinized gingiva >2 mm with distance of 1.5 mm from the CEJ to alveolar crest.
- **1b**—APE-II: Keratinized gingiva ≤2 mm with distance of 1.5 mm from the CEJ to alveolar crest.
- **1c**—APE-I-AAE: Keratinized gingiva >2 mm with insufficient distance from the CEJ to alveolar crest.
- **1d**—APE-II-AAE: Keratinized gingiva ≤2 mm with insufficient distance from the CEJ to alveolar crest.